

Otterbein University

Digital Commons @ Otterbein

Nursing Student Class Projects (Formerly MSN)

Student Research & Creative Work

Summer 2021

Disseminated Intravascular Coagulation (DIC)

Kahl Knapke
Otterbein University

Follow this and additional works at: https://digitalcommons.otterbein.edu/stu_msn



Part of the [Critical Care Nursing Commons](#)

Recommended Citation

Knapke, Kahl, "Disseminated Intravascular Coagulation (DIC)" (2021). *Nursing Student Class Projects (Formerly MSN)*. 480.

https://digitalcommons.otterbein.edu/stu_msn/480

This Project is brought to you for free and open access by the Student Research & Creative Work at Digital Commons @ Otterbein. It has been accepted for inclusion in Nursing Student Class Projects (Formerly MSN) by an authorized administrator of Digital Commons @ Otterbein. For more information, please contact digitalcommons07@otterbein.edu.

Disseminated Intravascular Coagulation

Kahl Knapke, BSN, RN, CCRN, SRNA
Otterbein University, Westerville, Ohio

Introduction: Disseminated Intravascular Coagulation

- Disseminated Intravascular Coagulation (DIC) is a deadly thrombohemorrhagic disorder brought on by a secondary illness (Schub & Balderrama, 2018).
- In all hospitalized patients admitted to the intensive care unit (ICU), DIC accounts for roughly 19% (Boral et al., 2016).
- The mortality rate for the most severe cases of DIC can be up to 78% (Boral et al., 2016).
- Determining the onset and duration of DIC can be tricky and often prolonged.

Why Disseminated Intravascular Coagulation?

- DIC was first clinically observed in the 19 century, but only over the past few decades has a comprehension of its pathogenesis been achieved (Papageorgiou et al., 2018).
- DIC can emerge from commonly seen diagnoses in the health care setting.
- Sepsis, trauma, malignancy, complications from obstetrics, vascular deformities, immunological reactions, and post-arrest recovery are most notably linked as precipitating conditions leading to DIC (Levi & Scully, 2018).
- DIC is only scrutinized by health professionals when there is a presentation of substantial, uncontrolled bleeding, even though organ dysfunction from microvascular ischemia gives rise to DIC too (Thachil, 2016).
- As anesthesia was taken seriously, identified early and be able to intervene promptly.

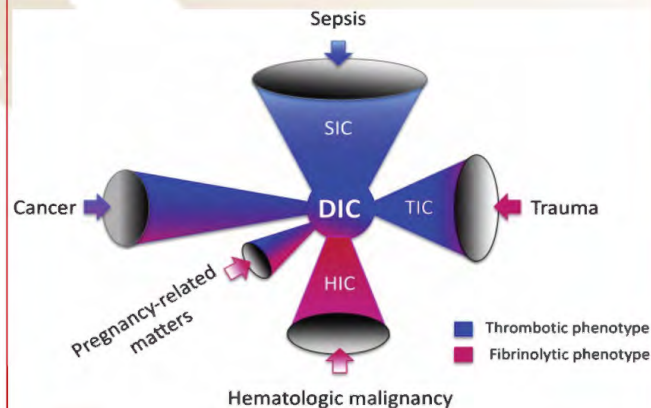
Pathophysiological Processes

Signs & Symptoms

- Distinct bleeding and oozing is often times the first discovered sign of DIC (Schub & Balderrama, 2018).
- Unforeseen bruising, bleeding from multiple areas (e.g., nose, gums, vagina, wounds and venipuncture sites) to name a few (Schub & Balderrama, 2018).
- Severe pain in the back, chest and chest (Schub & Balderrama, 2018).
- Tachycardia, hypotension, shortness of breath, and altered mental status have been noted (Schub & Balderrama, 2018).
- Patients can have abnormal lab values and be asymptomatic with low grade DIC (Schub & Balderrama, 2018).
- There is not one definitive laboratory (lab) test for DIC (Smith, 2021).
- Diagnostic lab test such as prolonged prothrombin time (PT), and activated partial thromboplastin time (aPTT), low fibrinogen, elevated D-dimer, and thrombocytopenia aid in DIC diagnosis (Smith, 2021).

Underlying Pathophysiology

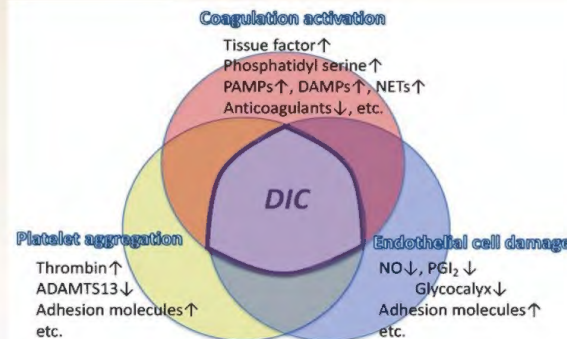
- DIC is a condition where clotting activation overcomes the body's own natural anticoagulants to produce excessive thrombus which results in depletion of coagulation factors and platelets leading to excessive bleeding (Levi, 2018).
- DIC can be differentiated as either be Acute or Chronic (Boral et al., 2016).
- Acute DIC is a consumption coagulopathic state caused by creating a surplus of thrombin that out number's normal anticoagulants as a result of elevated tissue factor in the intravascular space (e.g., infection, transfusion reactions, trauma/crush injury, burns, transplant rejections) to list a few (Boral et al., 2016).
- Chronic DIC precipitates from prolonged exposure to smaller amounts of thrombin (e.g., malignancies, metastasis, intrauterine fetal death, hematomas, aneurysms and vasculitis) to name a few (Boral et al., 2016).



(Iba et al., 2019, Figure 1)

Significance of Physiology

- To comprehend DIC, one must understand normal physiological hemostasis. Normal physiological hemostasis is achieved through formation of a platelet plug from platelet adhesion and aggregation, then followed by the activation of the coagulation cascade to form a fibrin clot. A sequence of enzymatic steps allow for thrombin to form. Next, thrombin is converted to soluble fibrinogen and then to an insoluble fibrin clot that forms a mesh including the previously noted platelet plug (Boral et al., 2016).
- The normal physiological coagulation cascade is made up of two pathways, intrinsic and extrinsic. The intrinsic pathway is comprised in order of factor XII, XI, IX, and VIII. The extrinsic pathway is initiated by Tissue Factor (TF) or factor III and then to factor VII. Both pathways lead to the final common pathway activating factor X, V, II, I (fibrin) (Boral et al., 2016).
- International Society on Thrombosis and Haemostasis (ISTH) is one of several scoring systems used to aid in DIC diagnosis (Smith, 2021).
- Worldwide, ISTH has been adopted as the gold standard for DIC diagnosis (Iba & Levy, 2020).
- Diagnostic algorithm for acute DIC developed by the Scientific Subcommittee on DIC of the ISTH uses common coagulation tests and the patient needs to have a disease associated with DIC. The algorithm has a 93% sensitivity and 97% specific for acute DIC (Boral et al., 2016).



(Iba, & Levy, et al., 2019, Figure 2)

Treatment

- The first initial step in treating DIC is to remove the underlying causative source (e.g., trauma, infection, malignancy, reactions, etc.) (Papageorgiou et al., 2018).
- Next, treatment strategy and options should closely be reflective of the most recent set of lab values such as PT/INR, PTT, platelet count, fibrinogen, and D-dimer (Papageorgiou et al., 2018).
- The uses of new global coagulation assays like whole blood thromboelastography/thromboelastography (TEG) drives optimal treatment (Papageorgiou et al., 2018).
- Administer blood components: fresh frozen plasma (FFP) for INR >1.5, platelets for platelet count <50,000/μL, cryoprecipitate (cryo) for fibrinogen level <100 mg/dL and red blood cells (RBC) for hematocrit <21% (Boral et al., 2016).
- For patients with continued bleeding after blood component administration with evidence of hyperfibrinolysis syndrome, administer an antifibrinolytic like tranexamic acid (TXA). Heparin therapy may also be considered in hypercoagulability states with deep vein thrombosis (DVT) or pulmonary embolism (PE) (Boral et al., 2016).

Implications for Nursing Care

- For nurses and anesthesia professionals, it is imperative to perform a thorough history and physical assessment for each patient (Smith, 2021).
- Nurses and anesthesia professionals should display high-level clinical expertise and understanding to be able to quickly identify DIC as well as interpreting vital lab results (Smith, 2021).
- Being proactive and advocating with the multidisciplinary team for timely and appropriate orders and interventions (Smith, 2021).
- Providing exceptional patient and family education will allow for better understanding of current situation which will allow them to be better prepared for the treatment (Smith, 2021).
- Effective on-going communication between treatment team, patient, and their families is something that cannot be taken lightly.

Conclusions

- DIC is identified as a life-threatening medical condition that includes extensive activation of coagulation factors, leading to thrombotic events and organ dysfunction as well as simultaneous depletion of those coagulation factors contributing to massive, uncontrolled hemorrhaging (Levi & Scully, 2018).
- DIC is always a secondary complication from an underlying medical condition (Levi & Scully, 2018).
- The occurrence of DIC is uncommon in the average hospitalized patient but accounts for around 9%-19% of ICU admitted patients which carries a mortality rate between 45%-78% (Boral et al., 2016).
- Prompt identification of DIC is vital to applying life-saving interventions (Smith, 2021).
- Nursing should be knowledgeable and aware in the correct interventions based on all clinical indicators.

References

Boral, B. M., Williams, D. J., & Boral, L. I. (2016). Disseminated intravascular coagulation. *American Journal of Clinical Pathology*, 146(6), 670-680. <https://doi.org/10.1093/ajcp/aqw195>

Iba, T., & Levy, J. H. (2020). Sepsis-induced coagulopathy and disseminated intravascular coagulation. *Anesthesiology*, 132(5), 1238-1245. <https://doi.org/10.1097/ALN.0000000000003122>

Iba, T., Levy, J. H., Thachil, J., Wada, H., & Levi, M. (2019). The progression from coagulopathy to disseminated intravascular coagulation in representative underlying diseases. *Thrombosis Research*, 179, 11-14. <https://doi.org/10.1016/j.thromres.2019.04.030>

Iba, T., Levy, J., Raj, A., & Warkentin, T. (2019). Advance in the management of sepsis-induced coagulopathy and disseminated intravascular coagulation. *Journal of Clinical Medicine*, 8(5), 728. <https://doi.org/10.3390/jcm8050728>

Kell, D. B., & Pretorius, E. (2014). The simultaneous occurrence of both hypercoagulability and hypofibrinolysis in blood and serum during systemic inflammation, and the roles of iron and fibrin(ogen). *Integrative Biology*, 7(1), 24-52. <https://doi.org/10.1039/c4ib00173g>

Levi, M. (2018). Pathogenesis and diagnosis of disseminated intravascular coagulation. *International Journal of Laboratory Hematology*, 40, 15-20. <https://doi.org/10.1111/ijlh.12830>

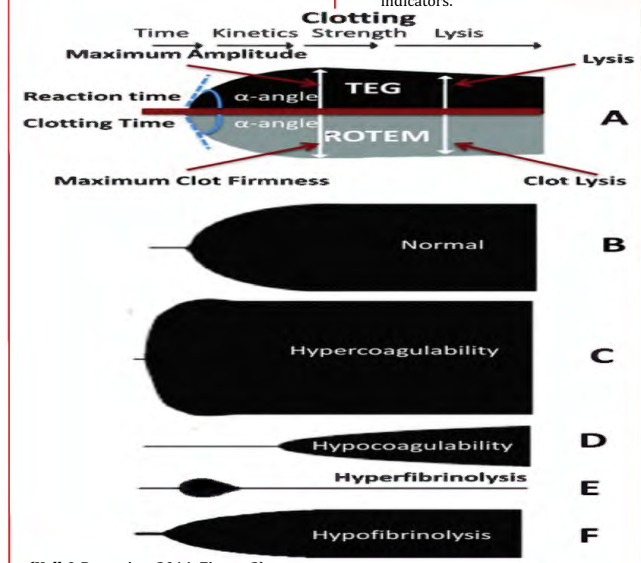
Levi, M., & Scully, M. (2018). How I treat disseminated intravascular coagulation. *Blood*, 131(8), 845-854. <https://doi.org/10.1182/blood-2017-10-804096>

Papageorgiou, C., Jourdi, G., Adjambri, E., Walborn, A., Patel, P., Fareed, J., Elalamy, I., Hoppensteadt, D., & Gerotziakas, G. T. (2018). Disseminated intravascular coagulation: An update on pathogenesis, diagnosis, and therapeutic strategies. *Clinical and Applied Thrombosis/Hemostasis*, 24(9_suppl), 85-285. <https://doi.org/10.1177/1076029618806424>

Schub, E., & Balderrama, D. (2018). Disseminated Intravascular Coagulation (DIC). *CINAHL Nursing Guide*. <https://web-b-ebcshost.com.ezproxy.otterbein.edu/ehost/pdfview/r/pdfviewer?vid=5&sid=1f62e452-0e56-490d-91db-43c490778c8a%40sessionmgm101>

Smith, L. (2021). Disseminated intravascular coagulation. *Seminars in Oncology Nursing*, 37(2), 1-4. <https://doi.org/10.1016/j.soncn.2021.151135>

Thachil, J. (2016). Disseminated intravascular coagulation. *Anesthesiology*, 125(1), 230-236. <https://doi.org/10.1097/ALN.0000000000001123>



(Kell & Pretorius, 2014, Figure 3)